CHEST

Advances in the Genetics of Primary Ciliary Dyskinesia

Clinical Implications

Amjad Horani, MD; and Thomas W. Ferkol, MD

Primary ciliary dyskinesia is a rare genetic disease of the motile cilia and is one of a rapidly expanding collection of disorders known as ciliopathies. Patients with primary ciliary dyskinesia have diverse clinical manifestations, including chronic upper and lower respiratory tract disease, left-right laterality defects, and infertility. In recent years, our understanding of the genetics of primary ciliary dyskinesia has rapidly advanced. A growing number of disease-associated genes and pathogenic mutations have been identified, which encode axonemal, cytoplasmic, and regulatory proteins involved in the assembly, structure, and function of motile cilia. Our knowledge of cilia genetics and the function of the proteins encoded has led to a greater understanding of the clinical manifestations of motile ciliopathies. These advances have changed our approach toward diagnostic testing for primary ciliary dyskinesia. In this review, we will describe how new insights into genetics have allowed us to define the clinical features of primary ciliary dyskinesia, revolutionize diagnostics, and reveal previously unrecognized genotype-phenotype relationships in primary ciliary dyskinesia.

CHEST 2018; 154(3):645-652

KEY WORDS: axoneme; bronchiectasis; cilia; ciliopathy; mucociliary clearance

The epithelium lining the nasopharynx, middle ear, paranasal sinuses, and larger airways are covered by motile cilia, and the mucociliary escalator is a critical local defense that protects the upper and lower respiratory tracts. Effective airway clearance is dependent on closely coordinated and regulated ciliary function, and any disturbance in the precise, orchestrated movement of cilia can cause disease.

Primary ciliary dyskinesia (PCD), previously known as immotile cilia syndrome, is a rare inherited ciliopathy and the first human disease linked to motile cilia dysfunction.[1] Estimated to occur in approximately one in 20,000 live births, its prevalence in children with chronic respiratory infections has been estimated to be as high as 5%.[2] Our understanding of the genetics, pathophysiology, and clinical manifestations of PCD has rapidly advanced

ABBREVIATIONS: PCD = primary ciliary dyskinesia

AFFILIATIONS: From the Department of Pediatrics (Drs Horani and Ferkol) and Department of Cell Biology and Physiology (Dr Ferkol), Washington University School of Medicine, St Louis, MO.

FUNDING/SUPPORT: The authors received support from the National Institutes of Health (NIH) [Grants HL096458, HL116211 to T. W. F.], National Health and Medical Research Council [Grant NHMRC1043768 to T. W. F.], American Thoracic Society Foundation-PCD Foundation-Kovler Family Foundation Partner Research Award [to A. H.], and the Washington University Children's Discovery Institute. The Genetic Disorders of Mucociliary Clearance Consortium [HL096458] is part of the NIH Rare Disease Clinical Research Network, supported through collaboration between the NIH Office of Rare Diseases Research at the National Center for Advancing Translational Science and the National Heart, Lung and Blood Institute.

CORRESPONDENCE TO: Thomas W. Ferkol, MD, Division of Pediatric Allergy, Immunology, and Pulmonary Medicine, Department of Pediatrics, 660 S Euclid Ave, Mailbox 8116, St Louis, MO 63110; e-mail: ferkol_t@wustl.edu

Copyright © 2018 American College of Chest Physicians. Published by Elsevier Inc. All rights reserved.

DOI: https://doi.org/10.1016/j.chest.2018.05.007

since the disease was linked to ultrastructural defects of the ciliary axoneme four decades ago.[1] In this review, we will summarize new insights into the biologic and genetic bases of PCD, leading to greater understanding of its clinical manifestations, greater understanding of genotype-phenotype relationships, and better diagnostics tools.

Cilia Structure and Function

Motile cilia are complex, specialized hair-like organelles that beat rhythmically, producing a metachronal wave that vectorially moves fluid and mucus from the conducting airways, paranasal sinuses, and eustachian tubes.[3] In addition, motile cilia are abundant on some epithelia outside the respiratory tract, including brain ventricles[4] and Fallopian tubes.[5] Flagella are analogous organelles that have a similar ultrastructure to cilia and propel spermatozoa.[6]

A ciliated airway epithelial cell has approximately 200 motile cilia that are anatomically and functionally oriented, moving with intracellular and intercellular synchrony along the length of the airway.[4] The motile cilium extends from the apical surface of the epithelial cell into the extracellular space and is anchored by a basal body, a structure derived from the centrosome.[7] The central fibrillar structure, or axoneme, is covered by a membrane separated by specialized proteins, distinct from the cell membrane.[8] Each cilium contains an array of helical protofilaments consisting of α- and β-tubulin monomers that build A and B microtubules. In normal motile cilia, these structures are organized as nine microtubular doublets arranged in an outer circle around a central pair, creating the characteristic 9 + 2 configuration observed in cross sections on transmission electron micrographs, an established method to evaluate motile cilia structure[1] (Fig 1).

The outer doublets of motile cilia have distinct inner and outer arms, consisting of several heavy, intermediate, and light chains, that are attached at repeated 96- and 24-nm intervals, respectively.[9] The axonemal dyneins in the outer dynein arm are multiheaded motor proteins that generate force through adenosine triphosphatase activity, translated into a controlled sliding motion of two neighboring tubules. The inner dynein arm regulates microtubule sliding and ciliary motion through the dynein regulatory complex, which consists of multiple proteins that coordinate activity of multiple dyneins and controls ciliary beat.[10] The dynein regulatory complex is located within the nexin link, an elastic element that tethers adjacent outer doublets and limits microtubular sliding. The radial spokes connect the central apparatus and outer doublets, and also regulate dynein activity, presumably though interactions with the dynein regulatory complex and inner dynein arm.

Intra- and intercellular regulation of ciliary motion is not fully understood, but several signaling mechanisms regulate ciliary beat frequency, such as airway nitric oxide.[11,12] Normal beat frequency of human motile cilia ranges between 8 and 14 beats/s, but motion can be altered by changes in the epithelial surface environment and various pollutants and infectious insults.[13,14]

Classified by their microtubular structure and functions, there are other forms of cilia. Primary or sensory cilia are solitary, immotile organelles that have 9 + 0 microtubule configuration (Fig 1) and are present on most cell types during interphase. They are vital signaling organelles that sense the extracellular environment and, depending on the cell type, serve as

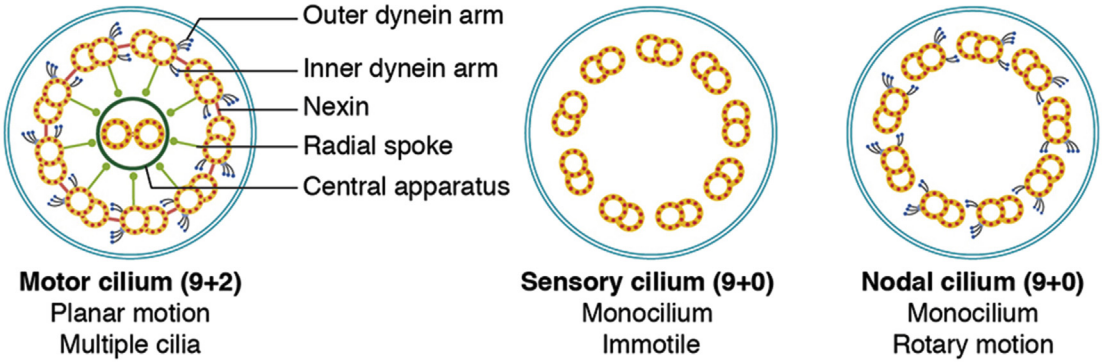

Figure 1 – *Schematic diagrams that show the microtubular structure and ultrastructural elements of normal motile 9 + 2, nonmotile primary 9 + 0, and motile nodal 9 + 0 ciliary axonemes.*

mechano-, chemo-, osmo-, photo-, and thermoreceptors. In addition, primary cilia play central roles in growth and repair, regulating many developmental pathways.[15,16] Genetic defects in primary cilia have been linked to an increasing number of clinically diverse conditions, collectively known as ciliopathies, which lead to neurocognitive impairment, blindness, obesity, diabetes, cardiac defects, and polycystic kidney diseases.[16]

Nodal cilia are a third class of cilia that are transiently expressed in the ventral node of the gastrula during embryonic development. These monocilia have a similar 9 + 0 microtubule arrangement as primary cilia (Fig 1) but contain dyneins that allow them to spin clockwise, generating leftward flow of extracellular fluid across the nodal surface.[17] This flow is detected by perinodal sensory cilia and activates a signaling cascade that establishes left-right sidedness.[18] In the absence of flow, left-right laterality is random, leading to laterality defects, such as situs inversus totalis and heterotaxy.[19] Likewise, nodal dysfunction is associated with congenital heart defects.[20]

Genetics of PCD

PCD is a genetically heterogeneous disease that does not have an apparent racial or sex predilection. Mutations in any protein involved in cilia assembly, structure, or function could theoretically cause disease, and a rapidly expanding number of genes have been implicated. In most cases, PCD is transmitted by an autosomal-recessive pattern of inheritance; however, X-linked inheritance patterns are known.[21,22]

The basic axonemal structure of motile cilia is evolutionarily conserved, and simple organisms, such as the biflagellated alga *Chlamydomonas reinhardtii*, have been used to understand the structure, function, and genetics of the human cilium.[23,24] In fact, most genes that have been associated with PCD have algal orthologues.[25] In patients, gene discovery has historically relied on a combination of experimental models and targeted screening of candidate genes encoding proteins in the ciliome. More recently, international collaboratives in Europe and North America have applied whole exome sequencing or massive parallel sequencing, which has led to identification of new genes.[25] Currently 40 genes have been associated with disease, and > 70% of patients tested have biallelic mutations in one of these genes. That number will certainly rise with further gene discovery. Many of the defective genes have been linked to specific ultrastructural elements, including those that encode proteins in the outer dynein arm, inner dynein arm, dynein regulatory complex, radial spokes, and central apparatus (Fig 2).[25] More recently, disease-causing mutations have been found in genes coding several cytoplasmic proteins not integral to the cilia axoneme, some of which form complexes essential for preassembly of dynein motor units.[26]

Ciliary beat patterns have also been linked to specific genetic and ultrastructural defects. Outer dynein arm defects, with or without inner dynein abnormalities, lead to virtually immotile cilia, whereas central apparatus defects create circular, whirling patterns.[27] However, pathogenic mutations in some genes, such as outer dynein arm protein DNAH11, have only subtle changes in beat frequency and ciliary motion.[28]

Clinical Manifestation of PCD

Because the genetics is better understood, we now recognize that PCD has four cardinal clinical features that distinguish it from other respiratory conditions of childhood.[29] Most children with PCD present shortly after birth as term newborns with respiratory distress, clinically manifested as tachypnea, persistent hypoxemia, and upper and middle lobe atelectasis on chest radiographs. Neonates are typically diagnosed with pneumonia and require supplemental oxygen or positive pressure ventilator support for several days to weeks. Children with PCD often develop persistent nonseasonal rhinitis and daily, year-round productive (wet) cough that begin in early infancy before 6 months of age. These symptoms may vary in severity but never fully resolve, even after antibiotic therapy. Bronchiectasis is common, often involving the anatomic right middle lobe and lingula. Left-right laterality defects occur in approximately one-half of patients with PCD, usually manifested as situs inversus totalis with transposition of the thoracic and abdominal organs. Some patients have heterotaxy associated with congenital heart disease, asplenia, and polysplenia.[19] Middle ear disease is frequently seen in PCD, with varying degrees of chronic otitis media with effusion often complicated by conductive hearing loss, but this clinical manifestation does not discriminate from children who do not have PCD.[29]

Genotype-phenotype differences are emerging. Differences in respiratory disease severity have been linked to specific genes. Biallelic loss-of-function

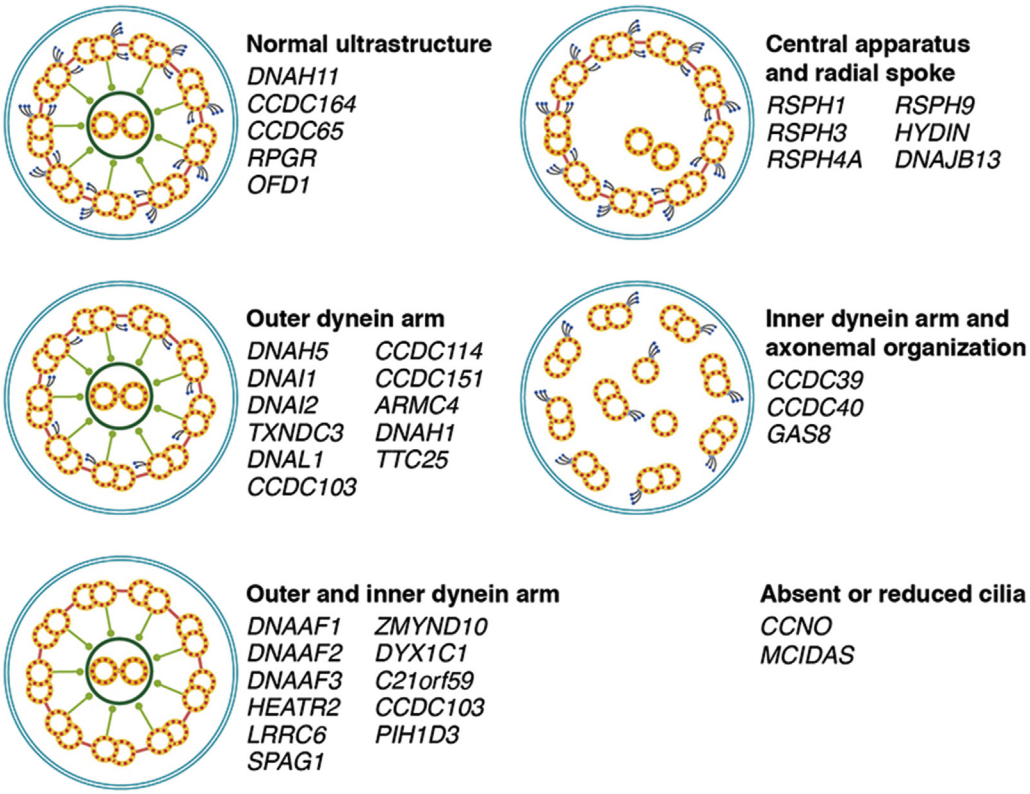

Figure 2 – *Classification of ultrastructural phenotypes of the ciliary axoneme and genes associated with primary ciliary dyskinesia.*

mutations in *CCDC39* and *CCDC40* cause ultrastructural abnormalities in the axoneme, characterized by absence of inner dynein arms and disorganized microtubules in some but not all cilia. CCDC39 and CCDC40 are integral to the nexin-dynein regulatory complex and function as molecular rulers, directing the accurate spacing and arrangement of the inner dynein arms and radial spokes.[30] A cross-sectional study showed that children with biallelic *CCDC39* or *CCDC40* mutations had more severe lung disease than individuals with dynein arm protein mutations.[31] Conversely, patients with mutations in *RSPH1* generally have only situs solitus and milder respiratory phenotypes, with later onset of cough and better lung function than other forms of PCD.[32] The explanation for these phenotypical differences is not entirely known. Motor ciliopathies are likely a spectrum, such that some biallelic pathogenic variants may not cause typical PCD but could result in moderately reduced cilia function and less severe clinical manifestations.[26,33] Indeed, two reports have suggested that different mutations in the same PCD-associated gene may result in variable disease severity.[26,33] Ciliary defects may be more common than previously appreciated, and subtle motile ciliary dysfunction could still lead to persistent respiratory diseases or potentially modify other lung diseases in the general population.

In addition to laterality defects, patients with PCD can have other extrarespiratory manifestations. Male and female subfertility are common because of sperm dysmotility and ciliary dysfunction in the Fallopian tubes, respectively. Recent studies have demonstrated a relationship between the affected gene and fertility phenotypes.[34] Although common in murine models, neonatal hydrocephalus is rarely seen in newborns with PCD, likely related to ciliary dysmotility in brain ventricles.[35] Finally, individuals with X-linked blindness related to mutations in *RPGR* have recurrent respiratory infections, demonstrating functional overlap between motile and primary cilia.[22] In actual fact, motile cilia respond to external stimuli such as bitter taste, indicating that these organelles can sense their environment like primary cilia.[36,37]

Diagnosis of PCD

Diagnostic approaches for PCD have evolved during the last decade, sparked by advances in our understanding of genetics and pathogenesis of the disease, and the availability of newer diagnostic tools (Table 1).

TABLE 1] Advantages and Disadvantages of Current Screening and Diagnostic Options for PCD in Patients Who Have a Compatible Clinical Phenotype

Diagnostic Test	Advantages	Limitations
Transmission electron microscopy	Historically considered the gold standard, can be diagnostic in 70% of cases	Dependent on adequate tissue collection Inexperience in processing and interpretation can lead to false-positive or false-negative results Acquired ciliary abnormalities may appear similar to PCD defects Absence of ultrastructural defects does not exclude diagnosis (eg, *DNAH11*)
Brightfield (light) microscopy	Easy to perform on freshly collected airway epithelial samples	Dependent on adequate tissue collection Nonstandardized technique Diagnostic accuracy is poor
Nasal nitric oxide measurements	Nasal nitric oxide levels are reproducibly reduced in PCD In patients ≥ 5 y of age, high sensitivity and specificity	Not validated in children < 5 y of age Cystic fibrosis must be excluded Patients with confirmed defects in some genes (eg, *RSPH1*) can have nondiagnostic results Nasal nitric oxide levels can be decreased during acute viral respiratory infections or sinusitis Currently, no FDA-approved devices
High-speed video microscopy	Provides assessment of cilia beat patterns and frequency	Dependent on adequate tissue collection Requires considerable skill and training; few international centers currently have the necessary expertise Lack of standardization in sample preparation and interpretation Interrater agreement of beat pattern analysis is low
Extended genetic panel testing (> 30 genes)	Diagnostic in > 70% of cases, including patients who have normal or nondiagnostic electron microscopic images	Negative genetic testing does not exclude diagnosis Pathogenic variants must be trans Variants of unknown significance can yield nondiagnostic results

FDA = Food and Drug Administration; PCD = primary ciliary dyskinesia.

Nevertheless, it is important that clinicians should only consider diagnostic testing in those patients who have a compatible clinical phenotype to reduce the likelihood of false-positive results. These phenotypes include neonatal respiratory distress in full-term infants, defined as supplemental oxygen or positive pressure support for > 48 h without clear explanation, left-right laterality defects, persistent nonseasonal rhinitis that begins early in life, and daily wet or productive cough that develops in infancy. If just two of these distinguishing clinical features are present, the sensitivity and specificity for PCD are 80% and 72%, respectively.[29] Without them, patients are unlikely to have PCD and further testing may not be indicated. A validated diagnostic predictive tool has been created to estimate the probability of a positive diagnosis, based on several predictive parameters (PICADAR), including these features.[38]

Transmission electron microscopy to assess for ultrastructural defects in the axoneme has long been considered the diagnostic gold standard, following the original description of dynein arm defects in subjects with PCD. However, the technique has several limitations as a diagnostic tool. The lack of ciliary defects does not exclude the diagnosis because 30% of patients who have PCD will have normal axonemal ultrastructure.[39] For instance, pathogenic variants in *DNAH11* are not associated with ultrastructural defects and cilia have normal or more rapid beat frequencies.[28] In addition, individuals with biallelic mutations in *MCIDAS* and *CCNO* have structurally normal oligocilia on their airway epithelium because of defects in centriole replication and basal body migration to the apical surface.[40,41] Because some ciliary abnormalities in PCD are not found in every axoneme,[31] these changes may be attributed to secondary defects. Cilia ultrastructural defects can be acquired, caused by epithelial cell insults, and caused by inflammation related to exposure to environmental pollutants and infections. For instance, ciliary disorientation was considered a form of PCD, but this phenomenon is likely the result of airway injury.[42] Indeed, our understanding of genetic bases of PCD

revealed six general ultrastructural phenotypes (Fig 2) and showed that inner dynein arm defects alone are rarely associated with disease.

Immunofluorescent staining of ciliary protein markers has been proposed as a method to detect ultrastructural abnormalities in PCD and may address some of the limitations of transmission electron microscopy. Although more studies are required, published reports have shown high sensitivity and specificity in detecting abnormal axonemal ultrastructure when combined with clinical criteria.[43] Newer investigative techniques, such as cryoelectron tomography, provide greater resolution and reveal previously imperceptible axonemal defects that cause disease.[44]

Nasal nitric oxide measurement has been widely adopted as a screening or diagnostic tool for PCD, based on the reproducible observation that affected individuals have reduced levels. Nitric oxide is thought to play a role in modulating motile cilia beating, and nitric oxide synthases are localized near basal bodies, which may provide clues concerning its intricate relationship with motile cilia.[45] However, the exact mechanism by which cilia dysfunction is related to reduced nasal nitric oxide remains unclear. Nasal nitric oxide measurements are sensitive and specific for the diagnosis of PCD in individuals $\geq$ 5 years of age, provided cystic fibrosis is excluded, and are currently recommended as part of diagnostic criteria at North American centers.[46] Younger children with PCD can similarly have lower nasal nitric oxide levels than their normal counterparts, but measurements are not recommended in this population because of the lack of normative data. Reduced nasal nitric oxide levels have been described in patients with chronic rhinosinusitis,[47] which emphasizes the need to thoroughly evaluate patients suspected of PCD and not rely on an individual test for diagnosis.

Because ciliary motion is generally uniform along the airway, functional assays have become part of the diagnostic evaluation of many European centers. Ciliary movement varies widely in PCD, from absent to near-normal movement. High-speed video microscopy has been used to assess motile ciliary beat frequency and patterns in freshly excised or cultured ciliated epithelia.[48] Ciliary beat frequency and motion can be affected by ambient temperature and handling of the tissue sample, which could lead to erroneous results.[49] Although cilia waveform analysis may become a promising diagnostic tool for PCD, especially as automated methods are validated and become clinically available,[50] the absence of standardization in sample handling and quantitative interpretation of beat patterns currently limits its applicability across centers.

Finally, with the availability of commercial gene panels, PCD genetic testing has grown in popularity and become a viable diagnostic tool. Several molecular diagnostic companies offer comprehensive genetic testing, providing relatively quick and accurate screening of most known disease-associated genes. In patients with clinical criteria suggestive of PCD, genetic testing should be part of a panel of diagnostic tests.[51] Identification of biallelic pathogenic variants in a known PCD-associated gene should be sufficient to make the diagnosis.

Treatment

Mutations associated with PCD result in abnormal protein function and structure of the cilia. To date, no clinically proven therapies have been shown to restore cilia function in PCD. Patients should perform airway clearance techniques regularly to augment mucociliary clearance and be treated with antimicrobials for pulmonary exacerbations, guided by surveillance sputum cultures.[51] Otherwise, there are no data that support routine use of other therapies, including nebulized hypertonic saline, mucolytics, or bronchodilators.

Conclusions

PCD is a rare inherited disease of the motile cilia, and its genetics have yielded new insights into its pathophysiology, defined clinical manifestations, and provided better diagnostic tools. Despite these advances, well-tested, effective treatments for PCD are lacking. To date, no therapies have been shown to correct ciliary dysfunction, but hopefully our growing understanding of cilia genes and their products will uncover novel targetable pathways that can restore ciliary structure and function in patients with PCD.

Acknowledgments

Financial/nonfinancial disclosures: The authors have reported to *CHEST* the following: A. H. and T. W. F. have served as investigators on a clinical trial for Parion Sciences, and T. W. F. was an investigator for a device trial supported by Circassia Pharmaceuticals.

Role of sponsors: The views expressed in this review do not necessarily reflect the official policies of the Department of Health and Human Services, nor does mention by trade names, commercial practices, or organizations imply endorsement by the US government.

References

1. Afzelius BA. A human syndrome caused by immotile cilia. *Science*. 1976;193(4250):317-319.

2. Chapelin C, Coste A, Reinert P, et al. Incidence of primary ciliary dyskinesia in children with recurrent respiratory diseases. *Ann Otol Rhinol Laryngol*. 1997;106(10):854-858.
3. Leigh MW, Pittman JE, Carson JL, et al. Clinical and genetic aspects of primary ciliary dyskinesia and Kartagener syndrome. *Genet Med*. 2009;11(7):473-487.
4. Banizs B, Pike MM, Millican CL, et al. Dysfunctional cilia lead to altered ependyma and choroid plexus function, and result in the formation of hydrocephalus. *Development*. 2005;132(23): 5329-5339.
5. Raidt J, Werner C, Menchen T, et al. Ciliary function and motor protein composition of human fallopian tubes. *Hum Reprod*. 2015;30(12):2871-2880.
6. Linck RW, Chemes H, Albertini DF. The axoneme: the propulsive engine of spermatozoa and cilia and associated ciliopathies leading to infertility. *J Assist Reprod Genet*. 2016;33(2):141-156.
7. Dawe HR, Farr H, Gull K. Centriole/basal body morphogenesis and migration during ciliogenesis in animal cells. *J Cell Sci*. 2007;120 (part 1):7-15.
8. Pazour GJ, Bloodgood RA. Targeting proteins to the ciliary membrane. *Curr Top Dev Biol*. 2008;85:115-149.
9. Roberts AJ, Kon T, Knight PJ, Sutoh K, Burgess SA. Functions and mechanics of dynein motor proteins. *Nat Rev Mol Cell Biol*. 2013;14(11):713-726.
10. Heuser T, Raytchev M, Krell J, Porter ME, Nicastro D. The dynein regulatory complex is the nexin link and a major regulatory node in cilia and flagella. *J Cell Biol*. 2009;187(6):921-933.
11. Li D, Shirakami G, Zhan X, Johns RA. Regulation of ciliary beat frequency by the nitric oxide-cyclic guanosine monophosphate signaling pathway in rat airway epithelial cells. *Am J Respir Cell Mol Biol*. 2000;23(2):175-181.
12. Wyatt TA, Spurzem JR, May K, Sisson JH. Regulation of ciliary beat frequency by both PKA and PKG in bovine airway epithelial cells. *Am J Physiol*. 1998;275(4):L827-L835.
13. Simet SM, Sisson JH, Pavlik JA, et al. Long-term cigarette smoke exposure in a mouse model of ciliated epithelial cell function. *Am J Respir Cell Mol Biol*. 2010;43(6):635-640.
14. Al-Rawi MM, Edelstein DR, Erlandson RA. Changes in nasal epithelium in patients with severe chronic sinusitis: a clinicopathologic and electron microscopic study. *Laryngoscope*. 1998;108(12):1816-1823.
15. Gerdes JM, Davis EE, Katsanis N. The vertebrate primary cilium in development, homeostasis, and disease. *Cell*. 2009;137(1):32-45.
16. Hildebrandt F, Benzing T, Katsanis N. Ciliopathies. *N Engl J Med*. 2011;364(16):1533-1543.
17. Nonaka S, Tanaka Y, Okada Y, et al. Randomization of left-right asymmetry due to loss of nodal cilia generating leftward flow of extraembryonic fluid in mice lacking KIF3B motor protein. *Cell*. 1998;95(6):829-837.
18. Yoshiba S, Shiratori H, Kuo IY, et al. Cilia at the node of mouse embryos sense fluid flow for left-right determination via Pkd2. *Science*. 2012;338(6104):226-231.
19. Kennedy MP, Omran H, Leigh MW, et al. Congenital heart disease and other heterotaxic defects in a large cohort of patients with primary ciliary dyskinesia. *Circulation*. 2007;115(22):2814-2821.
20. Nakhleh N, Francis R, Giese RA, et al. High prevalence of respiratory ciliary dysfunction in congenital heart disease patients with heterotaxy. *Circulation*. 2012;125(18):2232-2242.
21. Paff T, Loges NT, Aprea I, et al. Mutations in PIH1D3 cause X-linked primary ciliary dyskinesia with outer and inner dynein arm defects. *Am J Hum Genet*. 2017;100(1):160-168.
22. Moore A, Escudier E, Roger G, et al. RPGR is mutated in patients with a complex X linked phenotype combining primary ciliary dyskinesia and retinitis pigmentosa. *J Med Genet*. 2006;43(4):326-333.
23. Pazour GJ, Agrin N, Leszyk J, Witman GB. Proteomic analysis of a eukaryotic cilium. *J Cell Biol*. 2005;170(1):103-113.
24. Mitchell DR. The evolution of eukaryotic cilia and flagella as motile and sensory organelles. *Adv Exp Med Biol*. 2007;607: 130-140.
25. Horani H, Ferkol TW, Dutcher S, Brody SL. Genetics and biology of primary ciliary dyskinesia. *Paediatr Respir Rev*. 2016;18:18-24.
26. Horani A, Ustione A, Huang T, et al. Establishment of the early cilia preassembly protein complex during motile ciliogenesis. *Proc Nat Acad Sci USA*. 2018;115(6):E1221-E1228.
27. Chilvers MA, Rutman A, O'Callaghan C. Ciliary beat pattern is associated with specific ultrastructural defects in primary ciliary dyskinesia. *J Allergy Clin Immunol*. 2003;112(3):518-524.
28. Knowles MR, Leigh MW, Carson JL, et al. Mutations of DNAH11 in primary ciliary dyskinesia patients with normal ciliary ultrastructure. *Thorax*. 2012;67(5):433-441.
29. Leigh MW, Ferkol TW, Davis SD, et al. Clinical features and associated likelihood of primary ciliary dyskinesia in children and adolescents. *Ann Am Thor Soc*. 2016;13(8):1305-1313.
30. Oda T, Yanagisawa H, Kamiya R, Kikkawa M. A molecular ruler determines the repeat length in eukaryotic cilia and flagella. *Science*. 2014;346(2611):857-860.
31. Davis SD, Ferkol TW, Rosenfeld M, et al. Clinical features of childhood primary ciliary dyskinesia by genotype and ultrastructural phenotype. *Am J Respir Crit Care Med*. 2015;191(3):316-324.
32. Knowles MR, Ostrowsk LE, Leigh MW, et al. Mutations in RSPH1 cause primary ciliary dyskinesia with a unique clinical and ciliary phenotype. *Am J Respir Crit Care Med*. 2014;189(6): 707-717.
33. Shoemark A, Moya E, Hirst RA, et al. High prevalence of CCDC103 p.His154Pro mutation causing primary ciliary dyskinesia disrupts protein oligomerisation and is associated with normal diagnostic investigations. *Thorax*. 2018;73(2):157-166.
34. Vanaken GJ, Bassinet L, Boon M, et al. Infertility in an adult cohort with primary ciliary dyskinesia: phenotype-gene association. *Eur Respir J*. 2017;50(6):1700314.
35. Wessels MW, den Hollander NS, Willems PJ. Mild fetal cerebral ventriculomegaly as a prenatal sonographic marker for Kartagener syndrome. *Prenat Diagn*. 2003;23(3):239-242.
36. Christensen ST, Pedersen LB, Schneider L, Satir P. Sensory cilia and integration of signal transduction in human health and disease. *Traffic*. 2007;8(2):97-109.
37. Shah AS, Ben-Shahar Y, Moninger TO, Kline JN, Welsh MJ. Motile cilia of human airway epithelia are chemosensory. *Science*. 2009;325(5944):1131-1134.
38. Behan L, Dimitrov BD, Kuehni CE, et al. PICADAR: a diagnostic predictive tool for primary ciliary dyskinesia. *Eur Respir J*. 2016;47(4):1103-1112.
39. Knowles MR, Daniels LA, Davis SD, Zariwala MA, Leigh MW. Primary ciliary dyskinesia. Recent advances in diagnostics, genetics, and characterization of clinical disease. *Am J Respir Crit Care Med*. 2013;188(8):913-922.
40. Boon M, Wallmeier J, Ma L, et al. MCIDAS mutations result in a mucociliary clearance disorder with reduced generation of multiple motile cilia. *Nat Commun*. 2014;5:4418.
41. Wallmeier J, Al-Mutairi DA, Chen CT, et al. Mutations in CCNO result in congenital mucociliary clearance disorder with reduced generation of multiple motile cilia. *Nat Genet*. 2014;46(6):646-651.
42. Rayner CF, Rutman A, Dewar A, Cole PJ, Wilson R. Ciliary disorientation in patients with chronic upper respiratory tract inflammation. *Am J Respir Crit Care Med*. 1995;151(3):800-804.
43. Shoemark A, Frost E, Dixon M, et al. Accuracy of immunofluorescence in the diagnosis of primary ciliary dyskinesia. *Am J Respir Crit Care Med*. 2017;196(1):94-101.
44. Lin J, Yin W, Smith MC, et al. Cryo-electron tomography reveals ciliary defects underlying human RSPH1 primary ciliary dyskinesia. *Nat Commun*. 2014;5:5727.

45. Pifferi M, Bush A, Maggi F, et al. Nasal nitric oxide and nitric oxide synthase expression in primary ciliary dyskinesia. *Eur Respir J*. 2011;37(3):572-577.

46. Leigh MW, Hazucha MJ, Chawla KK, et al. Standardizing nasal nitric oxide measurement as a diagnostic test for primary ciliary dyskinesia. *Ann Am Thorac Soc*. 2013;10(6):574-581.

47. Lindberg S, Cervin A, Runer T. Nitric oxide (NO) production in the upper airways is decreased in chronic sinusitis. *Acta Otolaryngol*. 1997;117(1):113-117.

48. Lucas JS, Barbato A, Collins SA, et al. European Respiratory Society guidelines for the diagnosis of primary ciliary dyskinesia. *Eur Respir J*. 2017;49(1):1601090.

49. Konietzko N, Nakhosteen JA, Mizera W, Kasparek R, Hesse H. Ciliary beat frequency of biopsy samples taken from normal persons and patients with various lung diseases. *Chest*. 1981;80(6 suppl): 855-857.

50. Quinn SP, Zahid MJ, Durkin JR, Francis RJ, Lo CW, Chennubhotla SC. Automated identification of abnormal respiratory ciliary motion in nasal biopsies. *Sci Transl Med*. 2015;7(299):299ra124.

51. Shapiro AJ, Zariwala MA, Ferkol T, et al. Diagnosis, monitoring, and treatment of primary ciliary dyskinesia: PCD foundation consensus recommendations based on state of the art review. *Pediatr Pulmonol*. 2016;51(2):115-132.